



Received: 08 May 2018
Accepted: 12 September 2018
First Published: 17 September 2018

*Corresponding author: Mag. Margit Eidenberger, University of Applied Sciences for Health Professions, Austria
E-mail: Margit.Eidenberger@fhgooe.ac.at

Reviewing editor:
Omid Khaiyat, Liverpool Hope University, UK

Additional information is available at the end of the article

PEDIATRICS | CASE REPORT

Manual lymphatic drainage with infantile klippel-trenaunay syndrome: Case report and literature review

Mag. Margit Eidenberger^{1*}

Abstract: Aim: Klippel-Trenaunay Syndrome is a rare vascular malformation combining venous and lymphatic dysfunctions, oedema and limb overgrowth. Manual Lymphatic Drainage is an efficient therapy in lymphoedemas, but has scarcely been tried in infantile Klippel-Trenaunay Syndrome.

Method: Case Report of a two-year-old girl suffering from congenital Klippel-Trenaunay-Syndrome with oedema of the right upper limb and trunk quadrant. The girl was treated with MLD in combination with Compression Therapy until a compression sleeve could be fitted.

Results: Arm circumference measurements showed significant differences at wrist and elbow level, when taking the healthy arm as control, also skin temperature was significantly different. MLD could improve oedema during the therapy session, but not in the long term. There was no limb overgrowth during the observation period. MLD therapy protocol had to be interrupted because of thrombophlebitis episodes. Cautious CT including fingers up to axillary region is possible in breast-fed infants and toddlers. Close cooperation with the parents is crucial for therapy adherence and maintenance.

ABOUT THE AUTHOR

Margit Eidenberger is an Austrian physiotherapist since 1987. She received her physiotherapy degree in Vienna. From the beginning she specialized in oncology. Since 1991 she teaches at the University of Applied Sciences for Health Professions Upper Austria. Her subjects are Manual Lymphatic Drainage, Internal Medicine, Visceral Surgery and scientific courses. In addition, she works in a private practice with oncology as main area. She teaches Dr Vodder's Manual Lymphatic Drainage in Austria and abroad. She is currently writing her doctoral thesis.

Her key research activities are Manual Lymphatic Drainage, as well as evidence based medical education in theory and praxis, the latter with other colleagues from the Bachelor's programme for physiotherapy. The current study represents the latest case-report in a series with other unique or new indications for Manual Lymphatic Drainage, such as seroma after breast reconstruction or facial paralysis after Schwannoma surgery.

PUBLIC INTEREST STATEMENT

Finding new treatment options for congenital venous malformations in babies and little children is crucial. This article is about a malformation called Klippel-Trenaunay Syndrome. Although the disease is rare, parents and affected persons are in need of an efficient therapy free of side effects.

This research was inspired by a young family whose little girl suffered from oedema of the right upper limb and their search for therapy. The malformation can lead to disfiguring hypergrowth of the arm.

Being a specialist for Manual Lymphatic Drainage, a technique to resolve swelling, the idea to try this very gentle, massage-like therapy with this patient, was natural. Manual Lymphatic Drainage also includes a second pillar: the use of compression bandages or sleeves.

In this case, Manual Lymphatic Drainage reduced swelling in the short term, compression therapy in the long-term. This therapy can be a powerful option for a broad spectrum of oedema problems.

Conclusion: MLD and CT can be applied as a combination in small children with specific adaptations, with CT remaining the first line of therapy.

Subjects: Physiotherapy and Sports Medicine; Children and Youth; Paediatrics & Child Health; Physiotherapy

Keywords: Infantile Klippel-Trenaunay Syndrome; manual lymphatic drainage; compression therapy

1. Introduction

Klippel-Trenaunay's syndrome (KTS) is a rare vascular mesenchymal malformation with varying data concerning prevalence (1 per 30.000 (Husmann, Rathburn, & Driscoll, 2007) or 1 per 100.000 (Lorda-Sanchez, Prieto, & Rodriguez-Pinilla, 1998)). It was first described by Hilaire in 1832 (Oduber, van der Horst, & Hennekam, 2008) and in 1900 by Maurice Klippel and Paul Trenaunay (Jacob et al., 1998). It is characterized by multiple venous and lymphatic dysfunctions (Clayton & Irvine, 2008; Witte & Witte, 1987). Possible complications are internal haemorrhages (Wang, Wang, Zhu, & Liu, 2010), or pulmonary embolism (Douma et al., 2012; Hudcova, Kleinman, & Talmor, 2009). Haemangiomas, soft tissue- and bone hypertrophies or overgrowth of whole limbs (Oduber et al., 2008), predominantly located in lower extremities (Jacob et al., 1998), are present. Typical features are port-wine stains and venous varicosities in addition to deep venous anomalies. Noel and colleagues identified four reasons for the venous insufficiency: aplasia, hypoplasia, valve incompetence or aneurysm (Noel et al., 2000). Chen and colleagues suggested an increased AGGF1-expression during embryogenesis, leading to increased angiogenesis and lumen diameter of veins (Chen, Li, Tu, Yin, & Wang, 2013). Tian et al. provided an in-depth analysis of two gene defects in KTS (Tian et al., 2004).

There is an incoherence in clear diagnostic criteria, which can lead to delayed diagnosis or even misdiagnosis (KTS Working Group, Vascular Anomalies Center, 2016). Diagnosis is made according to clinical symptoms as well as ultrasonography, contrast venography, angiography and magnetic resonance lymphangiography (Dutt & Dutt, 2012; Lichte, Geyer, Benedix & Strölin, 2009; Lohrmann, Bartholomä, Foeldi, Speck, & Langer, 2007, Witte & Witte, 2000). Delis et al. assessed a cohort of 15 KTS patients classifying KTS according to CEAP (Clinical condition/aetiology/anatomical location/pathophysiology) grades. Furthermore they investigated patient-reported symptoms, finding complaints of heaviness, aching and swelling in 100% and pain in 93%, respectively (Delis, Gloviczki, Wennberg, Rooke, & Driscoll, 2007). Maclellan and colleagues considered clear differentiation between various malformations a matter of urgency to provide adequate therapy (Maclellan, Chaudry, & Greene, 2016).

Because of the diseases' rarity only scarce evidence is available of how to treat KTS. Most studies are case reports (de Leon, Braun Filho, Ferrari, Guidolin, & Maffessoni, 2010, Mneimneh, Tabaja, & Klippel-Trenaunay, 2015). Debate continues about the best strategies for the management of KTS. Currently recommended management involves symptomatic compression therapy (CT) (Jacob et al., 1998; KTS Working Group, Vascular Anomalies Center, 2016) and interventional methods, such as vein sclerosis (Noel et al., 2000). Sclerotherapy is not carried out in small infants (Leung, Leung, & Fung et al., 2014; Nakahata et al., 2016), and higher patient numbers would be required (Nitecki & Bass, 2007). Sclerotherapy should be performed with ultrasonographic and fluoroscopic guidance, but is normally a safe procedure. Proposed agents are sodium tetradecryl sulphate or ethanolamine (Leung et al., 2014; Nakahata et al., 2016). Possible side effects are bruises or inflammation, compression is required afterwards (Worthington-Kirsch, 2005). Billington et al. refer to failed surgical interventions (Billington, Shah, Elston, & Payne, 2013), which underlines the need for evidence for conservative techniques. In 2010 Liu et al. (Liu, Lu, & Yan, 2010) published a paper in which they described common lymphatic disorders in KTS and highlighted the need for more academic research in the field of lymphatic system dysplasia with KTS. McRae et al. have shown that a multidisciplinary approach including dermatology, diagnostic- and

interventional radiology, haematology, paediatric surgery, physiotherapy and social services should be considered (McRae, Adams, & Pereira et al., 2013). The KTS Working Group advocated an early treatment approach (KTS Working Group, Vascular Anomalies Center, 2016), as did Billington et al., who also recommended a multi-treatment plan (Billington et al., 2013).

So far, however, there has been little discussion about applying Manual Lymphatic Drainage (MLD) to KTS. Only Lichte et al. proposed implementing this method (Lichte et al., 2009) and Capraro et al. suggested implementing intermittent pneumatic compression to treat the lymphedema component in KTS (Capraro, Fisher, Hammond, & Grossman, 2002). MLD is a decongestive therapy largely used after oncologic surgery, such as for breast cancer, but also for various venous diseases (Molski, Ossowski, Hagner, & Molski, 2009; Dos Santos Crisóstomo, Candeias, Ribeiro, 2014). The objectives of MLD are to improve lymphangiomotoricity, as well as venous backflow (Downey et al., 2008; Tan et al., 2011). However, a problem with MLD is using it on young children. Furthermore Heinig and Wollina draw our attention to the combination of MLD with multi-layer compression bandages or patient-customized garments (Heinig & Wollina, 2015), also a challenging task in breastfed infants. Therefore, this paper seeks to address the following question: is a combination of MLD and CT a possible therapeutic option in infantile KTS?

2. Methods

A case-report approach was adopted to address the aforementioned question in a most practical way. The case of a now 29-month-old girl with KTS of the right upper limb and the right trunk is presented. The girl was born in November 2015 with idiopathic, presumably hereditary KTS, evaluated as blueish discolouration on the whole right upper limb, including the shoulder region and the ventral and dorsal thoracic wall (cp. Figure 4). Immediately after delivery there was no oedema present in the mentioned regions, but it began to develop in February 2016. Ultrasound scan of the head and the abdomen was inconclusive. The port-wine stains were painless, sonography could eliminate a somatic affection of the inner thoracic and abdominal organs, secondary haemostasis was within the normal range, magnetic resonance was postponed because of the required anaesthesia.

Thrombophlebitis, which is common in KTS, was first diagnosed in April 2017, and has occurred twice since then. Because of the absence of arteriovenous fistulas, as well as lymphatic malformation, it was diagnosed as a mild form of KTS, but a deterioration of the swelling was expected, as showed to be the case. The diagnosis of absence of lymphatic malformations was based on clinical decisions only.

The girl was referred to standard physiotherapy in February 2016 with KTS, muscular hypertonia and developmental delay (10 sessions) and then to Manual Lymphatic Drainage in April 2016. She was treated for 17 months with MLD and CT by two experienced lymph therapists at the children's ward for physiotherapy at the hospital in Steyr, Austria, the University of Applied Sciences for Health Professions and the author's private practice.

MLD therapy, according to Dr. Vodder's method consisted once a week of treatment of the neck (stationary circles on jugular nodes, supraclavicular nodes and occipital nodes, i.e. Profundus/Occiput-Terminus), the left axillary region (stationary circles on lateral thorax), the right axillary region (detour over ventral and dorsal sagittal watershed with finger circles, so-called windscreen wipers) and the whole right upper extremity (stationary circles, pumps, scoops and thumb circles, adapted to anatomic region). Particularly, emphasis with special grips was laid on certain problem areas (dorsal forearm and thumb region with stationary circles and thumb circles). One MLD treatment lasted 45 min. CT included the fingers and the whole right upper limb up to the axillary region (cp. Figure 5). The girl's mother was instructed to apply the CT on a daily basis at home in a three-staged procedure: after instruction by the therapist she was asked to practice it also on healthy family members for one week. Subsequently she had to bandage the therapist's arm to obtain feedback on her technique and finally she was asked to bandage her daughter's arm under supervision. CT commenced with two hours a day and was extended to three, maximum four hours a day in the course of the therapy.

Data consisted of circumference measurement in cm at three different measurement points: wrist, elbow and axilla and further by limb length measurement (distance between measurement points 1 and 3), photography and skin temperature. To accurately guarantee the same measurement points at each evaluation the following anatomical markers were used: distal end of the ulnar styloid, proximal end of the head of radius and the most proximal arm region. Skin temperature was measured with an infrared thermometer (Fa. ELV, modell 8889).

Prior to commencing the study, ethical clearance was sought from the ethical committee of Upper Austria, who decided that no application was required. The study followed the principles of the Declaration of Helsinki and the TIDier statement for reporting interventions. The girls' parents gave written consent to use the data gathered.

3. Results

The circumference measurement of the three different measurement points showed significantly different results when comparing the data of both arms at wrist and elbow level, but no significant difference at axillary level (cp. Figure 1, Figure 2). MLD could improve oedema during the therapy session, but not in the long term. There was no obvious difference in arm length measurement. Skin temperature showed significant differences when comparing the arms (cp. Figure 3).

The motoric development of the girl's right arm and the overall development was normal after having completed the standard physiotherapy. The affected arm had difficulty unfolding the thumb from the babies' fist position into opposition. Daily adherence to CT was excellent.

It was not possible to maintain the therapy protocol as intended, because according to MLD contraindications, such as infectious diseases, adverse reactions to vaccinations, and additionally after occurrences of thrombophlebitis, the MLD had to be postponed. This postponement did not apply to the CT.

4. Discussion

Previous research has shown that MLD can enhance lymphangiomotoricity (Downey et al., 2008; Tan et al., 2011), because smooth muscle cells of lymph collectors respond to a stimulus of passive skin stretching. This is exactly the mechanism triggered by the therapist's hands (Williams, 2010). The findings of the current study are consistent with those of Downey et al. (Downey et al., 2008) in the aspect that MLD improved the oedema extent during therapy, but this did not last for a longer time period. In accordance with this, a greater participation of the venous system was hypothesized. This is supported by Delis et al., who demonstrated a venous hypertension in KTS, leading to constant complex reflux patterns (Delis et al., 2007). With MLD the epifascial lymphatic vessels in

Figure 1. Arm circumference measurement for both arms.
Legend: LW, left wrist; LE, left elbow; LA, left axillary region; RW, right wrist; RE, right elbow; RA, right axillary region.

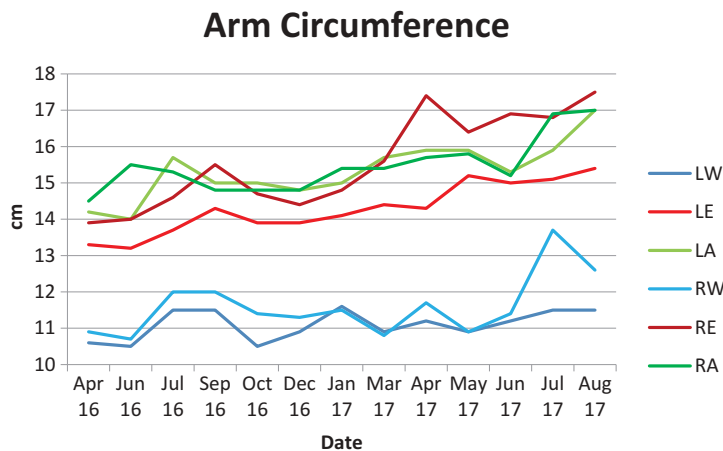


Figure 2. Arm length measurement.

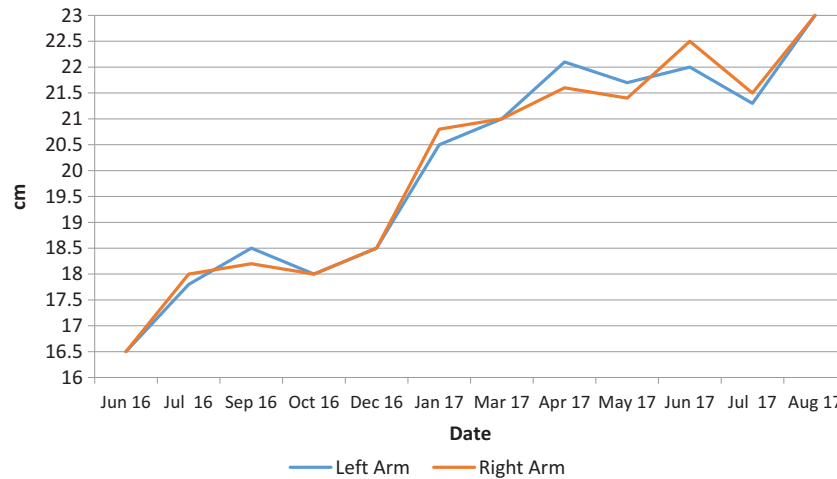
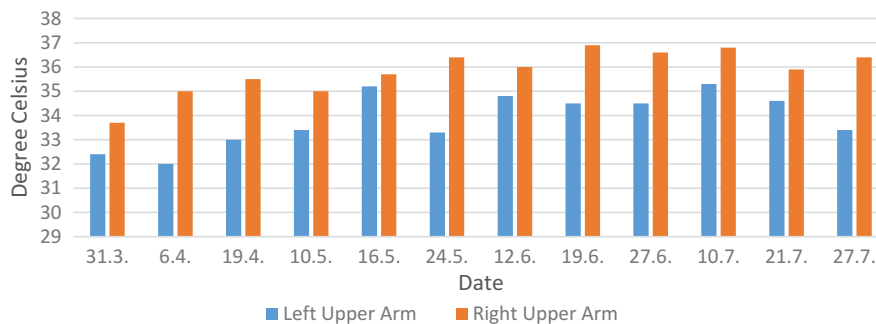


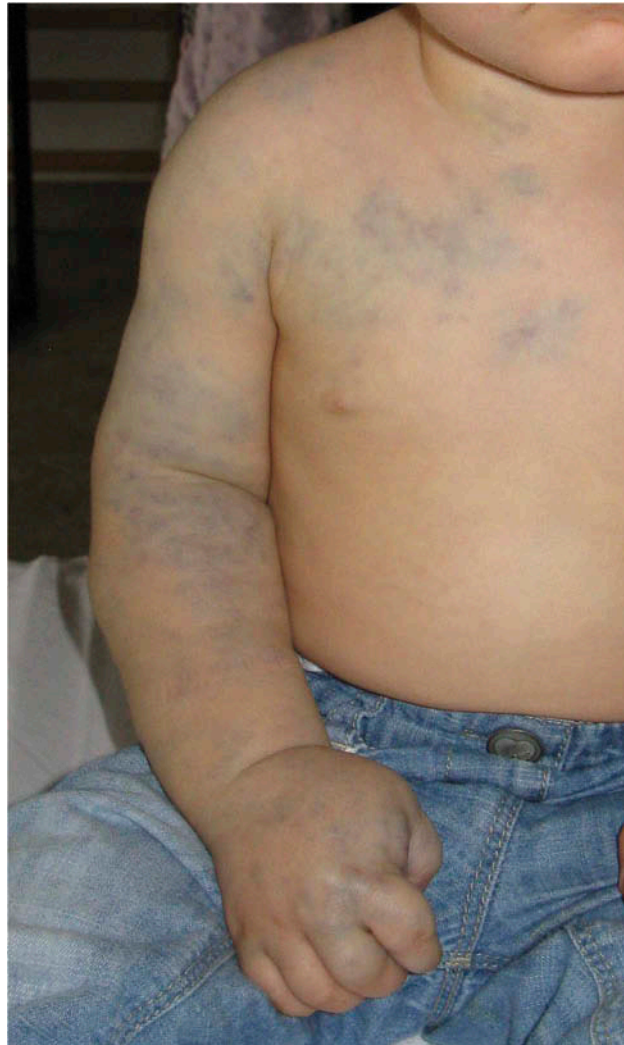Figure 3. Skin temperature.



the subcutaneous connective tissue are especially influenced, leading to increased microcirculation (Hutzschenreuter, Brümmer, & Eberfeld, 1989). Heinig and Wollina stressed the importance of pressure for the function of microcirculation (Heinig & Wollina, 2015). MLD is a repeated procedure of applying pressure and letting go; therefore, MLD seemed to be a justified therapeutic option. Microcirculatory disturbances in chronic venous insufficiency were documented in an older study by Carpentier et al. (Carpentier, Magne, Sarrot-Reynaud, & Franco, 1987), which led the authors to the conclusion that the use of MLD was a possible approach for controlling oedema. Furthermore Dos Santos Crisostomo et al. (Dos Santos Crisóstomo, Candeias & Armada-da-Silva, 2014) and Molski et al. (Molski et al., 2009) recommended MLD for this patient group. Because of KTS' venous components it should be possible to extrapolate the mentioned findings to KTS. Not all parts of the leg reacted in the same manner to the MLD strokes, as could be shown by the same authors in a very recent study (Dos Santos Crisóstomo, Candeias & Ribeiro, 2017), demonstrating a higher effect in the medial thigh. The medial thigh lies within the ventral medial bundle, which is crucial for the legs lymphatic flow.

MLD must be combined with patient adapted CT with multi-layer bandages and padding to achieve adequate tissue pressures during the rest of the day (Apich, 2013) and aims to prevent osteohypertrophy triggered by venous outflow impairment, in KTS especially (Björkholm & Aschberg, 1980). For Głowiczki and Driscoll (Głowiczki & Driscoll, 2007) and others (Clayton & Irvine, 2008; Clemens, Meier & Amann-Vesti, 2014) CT represents the hallmark of conservative management. Compression fitting must be observed closely in growing children to prevent constriction by the sleeve, because badly fitting CT can cause harm (Quéré et al., 2014). Only CT can establish a long-term decongestion (Vignes, Porcher, Arrault, & Dupuy, 2011) by increasing the tissue pressure and decreasing the filtration rate (Partsch, 2003). There is a risk of hindering the limb's motoric development with compression therapy,

Figure 4. Right arm and ventral thorax.



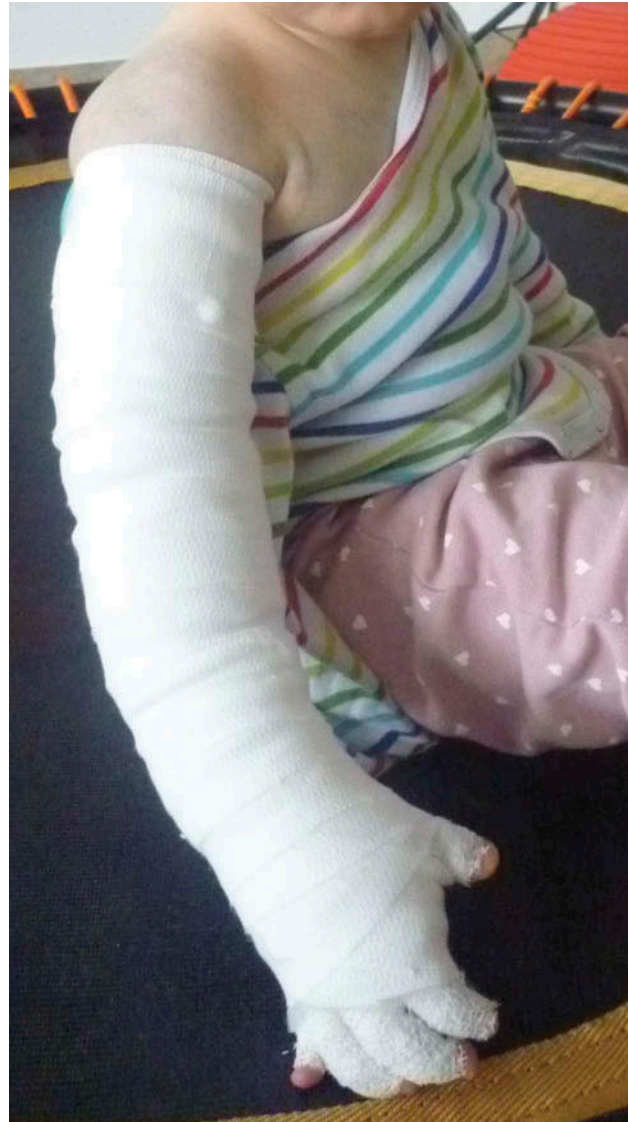so it was decided to limit the duration of compression therapy first to two hours a day. Later this was extended continually to four hours a day. A prior study mentioned the possibility of elastic compression to influence the course in KTS positively (Delis et al., 2007), as was the case in this report and could be shown also in the literature (Malgor & Labropoulos, 2011; National Institute for Health and Care Excellence, 2013). It was hypothesized that the small differences in arm length can be attributed to constant CT over 1.5 years, but this needs further observation.

More recently, customized compression garments are used (Vojáčková, Fialová, & Hercogová, 2012), but only in children over the age of two and with great caution, because of possible side effects. The suitable compression class for children was advised as grade I by Vollmer et al. (Vollmer, Pritschow, & Schuchhardt, 2008).

In case of the development of new thrombophlebitis a short delay of MLD is recommended because there is a small risk of thrombophlebitis developing into thrombosis (Shirasugi et al., 2016).

However, there are certain drawbacks associated with the use of MLD and CT in young children. The normal position taken by patients during MLD is resting supine and quietly on the practitioners' table. This proved to be impossible with the little girl, so therapy started in a supine position and changed later to sitting or even standing. Due to throat or other harmless infections it was not

Figure 5. Right arm with multi-layer compression.



possible to follow the weekly therapy protocol as intended, therefore there is some missing data in the analysis. Although this weakens the results, it is a more pragmatic than explanatory approach and supports the external validity (Mangold, 2013).

Psychosocial support for the child and its parents should be taken into consideration if considered helpful, because every chronic disease is a strain for the whole family (Capraro et al., 2002; KTS Working Group, Vascular Anomalies Center, 2016; Steinhausen, 1996). Chronically ill children need more care than healthy ones, therapy and assessment appointments must be met, sometimes with great effort. Education of the families should be incorporated into the therapy as invaluable elements. A close cooperation, especially with the mother parent, is critical for maintenance and continuity of both, MLD and CT.

Despite the difficulties in measuring agitated patients, circumference measurement has shown good intra-rater-reliability and test-retest reliability (Katz-Leurer & Bracha, 2012; Tidhar et al., 2015) and should therefore be established in the lymphtherapist's everyday practice as a feasible procedure. More sophisticated measurements, such as water displacement or perometry would

have shown the same limitations in young children and are in addition not feasible in private practice. Comparisons between perometer measurements and manual tape measurements showed a bias ranging from -5.5% to 1.5% depending on the measurement location (e.g. ulnar styloid and four subsequent 10 cm intervals up the arm in healthy adults). Foroughi et al. 2011 show a generally too small measurement by assessor vs. perometer (Foroughi et al., 2011).

Sporadic statements of displeasure occurring during MLD were traced back to tiredness, or the requirement to stay still for an extraordinary length of time (in childrens' terms). It seemed very unlikely that MLD produced pain during the treatment causing defence behaviour, because of MLD's pain-releasing effect (Hamner & Fleming, 2007; Zusman & Moog-Egan, 2003) and because MLD is free of side effects, if contraindication rules are followed.

Class I compression sleeves for children (Bringezu & Schreiner, 2014) were available for the first time in October 2017. MLD was suspended at the time of starting with the compression sleeve.

Another important finding was the significant difference in skin temperature between both arms. Increased skin temperature is common in venous disorders and KTS (Kelechi & Michel, 2007; McRae et al., 2013). The mean increase in skin temperature in this case report was 1.9°C . The temperature differed actually between 0.5 and 3.0° Celsius when compared to the healthy arm. Other reasons for this difference need to be taken into consideration: seasonal changes, whether the arm was bandaged or hanging down shortly before measurement. The infrared thermometer used has a measurement error of $\pm 2\%$ or 2°C , which limits the validity. However, an increased skin temperature should be treated with mild cryotherapy (Gerdemann, 2011), such as dabbing the arm with a cold wet washing glove. Outliers in circumference measurement at elbow level in April and again at wrist level in July (cp. Figure 1) need clarification: outside temperature must be taken into consideration. Additionally, the girl's activities could have played a role, because active muscle pump facilitates lymphatic and venous backflow (Moseley & Piller, 2008). Active movements of the affected limb should be promoted by carers as often as possible. This is especially useful in combination with CT (Godoy, Pereira, Oliani, & de Godoy, 2012). Delis et al. highlighted the impairment in the muscle pump function in venous disease (Delis et al., 2007) and MacRae refers to possible enlargement of venous malformations during physical activity (McRae et al., 2013).

5. Conclusion

The results of the current study indicate that the combination of MLD and CT is possible in small children. MLD in combination with CT is an additional therapeutic method in infantile KTS, with CT remaining the first line of therapy. Close observation is crucial of firstly limb development and possible hypertrophy, secondly overall motoric development and third, body growth, to not miss the time point for new compression garments.

6. Limitations

There are several possible sources of error. Long-term follow up on the KTS development would be recommended, although a follow-up of 1.5 years for a two-year old seems sufficient. Skin temperature should be monitored in future scientific work with valid measurement tools.

Acknowledgements

The author would like to thank Mr. Peter Orgill, MA for proofreading the paper.

Funding

This work was supported by the University of Applied Sciences for Health Professions Upper Austria, covering expenses, such as literature and publication fees.

Competing interests

The authors declare no competing interests.

Author details

Mag. Margit Eidenberger¹

E-mail: Margit.Eidenberger@fhgooe.ac.at

ORCID ID: <http://orcid.org/0000-0001-7040-931X>

¹ Bachelor Programme Physiotherapy, University of Applied Sciences Upper Austria, Steyr, Austria.

Citation information

Cite this article as: Manual lymphatic drainage with infantile klippel-trenaunay syndrome: Case report and

literature review, Mag. Margit Eidenberger, *Cogent Medicine* (2018), 5: 1524342.

References

- Apich, G. (2013). Konservative Therapie des Lymphödems - Lymphologische rehabilitationsbehandlung [Conservative therapy for lymphedema - Lymphologic rehabilitation]. *W MedWachenschr*, 163 (7-8), German 169-176. doi:10.1007/s10354-013-0205-5
- Billington, A. R., Shah, J., Elston, J. B., & Payne, W. G. (2013). Klippel-trenaunay syndrome. *Eplasty*, 13, ic64.
- Björkholm, M., & Aschberg, S. (1980). Functional aspects on the Klippel-Trénaunay and related syndromes. *Acta Dermato-Venereologica*, 60(5), 409-413.
- Bringezu, G., & Schreiner, O. (2014). *Lehrbuch der Entstauungstherapie: Grundlagen, Beschreibung und Bewertung der Verfahren, Behandlungskonzepte für die Praxis* [Coursebook of complex decongestive therapy]. 4. Aufl. Berlin, German: Springer.
- Capraro, P. A., Fisher, J., Hammond, D. C., & Grossman, J. A. (2002). Klippel-Trenaunay syndrome. *Plastic and Reconstructive Surgery*, 109(6), 2052-2060. quiz 2061-2.
- Carpentier, P., Magne, J. L., Sarrot-Reynaud, F., & Franco, A. (1987). Insuffisance veineuse chronique et microcirculation. Réflexions physiopathologiques et thérapeutiques [Chronic venous insufficiency and microcirculation. Pathophysiologic and therapeutic reflections]. *Journal des maladies vasculaires*, 12(3), 280-284. French.
- Chen, D. Li, L., Tu, X., Yin, Z., Yin, Z., & Wang, Q. (2013). Functional characterization of Klippel-Trenaunay syndrome gene AGGF1 identifies a novel angiogenic signaling pathway for specification of vein differentiation and angiogenesis during embryogenesis. *Human Molecular Genetics*, 22(5), 963-976. doi:10.1093/hmg/dd5501
- Clayton, T. H., & Irvine, A. D. (2008). Klippel-Trenaunay syndrome. *Journal Lymphoed*, 3(1), 48-50.
- Clemens RK, Meier TO, Amann-Vesti BR. (2014). Vaskuläre Malformationen - Diagnostik und Behandlung. [Vascular malformation - Diagnosis and treatment]. *Cardiovascular Medica*, 17(5), German 133-142. doi:10.4414/cvm.2014.00248
- de Leon, C. A., Braun Filho, L. R., Ferrari, M. D., Guidolin, B. L., & Maffessoni, B. J. (2010). Klippel-Trenaunay syndrome - case report. *Anais brasileiros de dermatologia*, 85(1), 93-96.
- Delis, K. T., Gloviczki, P., Wennberg, P. W., Rooke, T. W., & Driscoll, D. J. (2007). Hemodynamic impairment, venous segmental disease, and clinical severity scoring in limbs with Klippel-Trenaunay syndrome. *Journal Vas Surgery*, 45(3), 561-567. doi:10.1016/j.jvs.2006.11.032
- Dos Santos Crisóstomo RS, Candeias MS & Ribeiro AMM. (2014). Manual lymphatic drainage in chronic venous disease: A duplex ultrasound study. *Phlebology*, 29 (10), 667-676. doi:10.1177/0268355513502787
- Dos Santos Crisóstomo RS, Candeias MS, Armada-da-Silva PAS. (2017). Venous flow during manual lymphatic drainage applied to different regions of the lower extremity in people with and without chronic venous insufficiency: A cross-sectional study. *Physiotherapy*, 103(1), 81-89. doi:10.1016/j.physio.2015.12.005
- Douma, R. A., Oduber, C. E. U., Gerdes, V. E. A., van Delden, O. M., van Eck-Smit, B. L. F., Meijers, J. C. M., ... Bresser, P. (2012). Chronic pulmonary embolism in Klippel-Trenaunay syndrome. *Journal of the American Academy of Dermatology*, 66(1), 71-77. doi:10.1016/j.jaad.2010.12.002
- Downey, H. F., Durgam, P., Williams, A. G., Rajmane, A., King, H. H., & Stoll, S. T. (2008). Lymph flow in the thoracic duct of conscious dogs during lymphatic pump treatment, exercise, and expansion of extracellular fluid volume. *Lymphatic Research and Biology*, 6(1), 3-13. doi:10.1089/lrb.2007.1017
- Dutt, R., & Dutt, C. (2012). Klippel-Trenaunay-Weber syndrome. *Journal Clinical Neonatal*, 1(3), 160-161. doi:10.4103/2249-4847.101706
- Forbes, N., Walwyn, M., Rao, G., Ellis, D., Lee, M. G. (2013). Klippel-Trenaunay syndrome. *The West Indian Medical Journal*, 62(3), 254-256.
- Foroughi, N., Dylke, E. S., Paterson, R. D., Sparrow, K. A., Fan, J., Warwick, E. B. G., & Kilbreath, S. L. (2011). Inter-rater reliability of arm circumference measurement. *Lymphatic Research and Biology*, 9(2), 101-107. doi:10.1089/lrb.2011.0002
- Gerdemann, A. (2011). *Von Besenreisern und Varizen [About spider veins and varicosis]*. Pharmazeutische Zeitschrift online, Die Zeitschrift der deutschen Apotheker Vol. 46. ABDA - Bundesvereinigung Deutscher Apothekerverbände e. V., Berlin. Retrieved September 29, 2017 from <https://www.pharmazeutische-zeitung.de/index.php?id=40005>
- Gloviczki, P., & Driscoll, D. J. (2007). Klippel-Trenaunay syndrome: Current management. *Phlebology*, 22(6), 291-298.
- Godoy, M. F. G., Pereira, M. R., Oliani, A. H., & de Godoy, J. M. P. (2012). Synergic effect of compression therapy and controlled active exercises using a facilitating device in the treatment of arm lymphedema. *International Journal of Medical Sciences*, 9(4), 280-284. doi:10.7150/ijms.3272
- Hamner, J. B., & Fleming, M. D. (2007). Lymphedema therapy reduces the volume of edema and pain in patients with breast cancer. *Annals of Surgical Oncology*, 14(6), 1904-1908. doi:10.1245/s10434-006-9332-1
- Heinig, B., & Wollina, U. (2015). Komplexe physikalische Entstauungstherapie [Complex Decongestive Therapy]. *Der Hautarzt*, 66(11), German 810-818. doi:10.1007/s00105-015-3674-1
- Hudcova, J., Kleinman, M., & Talmor, D. (2009). Postoperative pulmonary embolism in a three year old with Klippel-Trenaunay syndrome. *International Medica Case Reports Journal*, 2, 1-5.
- Husmann, D. A., Rathburn, S. R., & Driscoll, D. J. (2007). Klippel-Trenaunay syndrome: Incidence and treatment of genitourinary sequelae. *The Journal of Urology*, 177(4), 1244-1249. doi:10.1016/j.juro.2006.11.099
- Hutzschenreuter, P., Brümmer, H., & Ebberfeld, K. (1989). Experimentelle und klinische Untersuchungen zur Wirkungsweise der manuellen Lymphdrainage-Therapie [Experimental and clinical assessments of effectiveness of manual lymphatic drainage]. *Z Lymphologie*, 13(1), 62-64. German.
- Jacob, A. G., Driscoll, D. J., Shaughnessy, W. J., Stanson, A. W., Clay, R. P., & Gloviczki, P. (1998). Klippel-Trénaunay syndrome: Spectrum and management. *Mayo Clinic Proceedings. Mayo Clinic*, 73(1), 28-36. doi:10.1016/S0025-6196(11)63615-X
- Katz-Leurer, M., & Bracha, J. (2012). Test-retest reliability of arm volume measurement in women with breast cancer-related lymphoedema. *Journal of Lymphoedema*, 7(2), 8-13.
- Kelechi, T. J., & Michel, Y. (2007). A descriptive study of skin temperature, tissue perfusion, and tissue oxygen in patients with chronic venous disease. *Biological Research for Nursing*, 9(1), 70-80. doi:10.1177/1099800407299424

- KTS Working Group, Vascular Anomalies Center. Clinical practice guidelines for Klippel-Trenaunay Syndrome (KTS). 2016; Retrieved September 14, 2017, from: <https://k-t.org/assets/images/content/BCH-Klippel-Trenaunay-Syndrome-Management-Guidelines-1-6-2016.pdf>.
- Leung, M., Leung, L., Fung, D., Poon, W. L., Liu, C., Chung, K., Tang, P., Tse, S., Fan, T. W., Chao, N., Lin, K. (2014). Management of the low-flow head and neck vascular malformations in children: The sclerotherapy protocol. *Zeitschrift für Kinderchirurgie : Organ der Deutschen, der Schweizerischen und der Österreichischen Gesellschaft für Kinderchirurgie = Surgery in infancy and childhood*, 24(1), 97–101.
- Lichte, V., Geyer, A., Benedix, F., Strölin, A. (2009). Thrombosis as a complication of the Klippel-Trenaunay syndrome and other vascular malformations. *Phlebology*, 38(3), 115–120.
- Liu, N. F., Lu, Q., & Yan, Z. X. (2010). Lymphatic malformation is a common component of Klippel-Trenaunay syndrome. *Journal of Vascular Surgery*, 52(6), 1557–1563. doi:10.1016/j.jvs.2010.06.166
- Lohrmann, C., Bartholomä, J. P., Foeldi, E., Speck, O., & Langer, M. (2007). Magnetic resonance lymphangiography in Klippel-Trenaunay syndrome. *The British Journal of Radiology*, 80(956), e188–92. doi:10.1259/bjr/46840541
- Lorda-Sanchez, I., Prieto, L., & Rodriguez-Pinilla, E. (1998). Increased parental age and number of pregnancies in Klippel-Trenaunay-Weber syndrome. *Annals of Human Genetics*, 62(Pt 3), 235–239. doi:10.1046/j.1469-1809.1998.6230235.x
- MacLellan, R. A., Chaudry, G., & Greene, A. K. (2016). Combined Lymphedema and Capillary Malformation of the Lower Extremity. *Plastic Reconstructive Surgery Glob Open*, 4(2), e618. doi:10.1097/GOX.0000000000000790
- Malgor, R. D., & Labropoulos, N. (2011). Treatment of chronic venous disease: Pathological underpinnings. *Medicographia*, 33(3), 259–267.
- Mangold, S. (2013). *Evidenzbasiertes Arbeiten in der Physio- und Ergotherapie* [Evidence based practice in physiotherapy and occupational therapy]. Berlin, German: Springer.
- McRae, M. Y., Adams, S., Pereira, J., Parsi, K., Wargon, O. (2013). Venous malformations: Clinical course and management of vascular birthmark clinic cases. *The Australasian Journal of Dermatology*, 54(1), 22–30. doi:10.1111/j.1440-0960.2012.00959.x
- Mneimneh, S., Tabaja, A., & Rajab, M. (2015). Klippel-Trenaunay Syndrome with Extensive Lymphangiomas. *Case Reports in Pediatrics*, Oct. 26, 581394.
- Molski, P., Ossowski, R., Hagner, W., & Molski, S. (2009). Patients with venous disease benefit from manual lymphatic drainage. *International Angiology : a Journal of the International Union of Angiology*, 28(2), 151–155.
- Moseley, A. L., & Piller, N. B. (2008). Exercise for limb lymphoedema: Evidence that it is beneficial. *Journal of Lymphoedema*, 3(1), 51–56.
- Nakahata, K., Uehara, S., Zenitani, M., Nakamura, M., Osuga, K., & Okuyama, H. (2016). Patient satisfaction after sclerotherapy of venous malformations in children. *Pediatrics International : Official Journal of the Japan Pediatric Society*, 58(8), 721–725. doi:10.1111/ped.12880
- National Institute for Health and Care Excellence. Varicose veins in the legs: The diagnosis and management of varicose veins. NICE clinical guideline 168. Manchester; 2013.
- Nitecki, S., & Bass, A. (2007). Ultrasound-guided foam sclerotherapy in patients with Klippel-Trenaunay syndrome. *The Israel Medical Association Journal: IMAJ*, 9(2), 72–75.
- Noel, A. A., Gloviczki, P., Cherry, K. J., Rooke, T. W., Stanson, A. W., & Driscoll, D. J. (2000). Surgical treatment of venous malformations in Klippel-Trenaunay syndrome. *Journal of Vascular Surgery*, 32(5), 840–847. doi:10.1067/mva.2000.110343
- Oduber, C. E., van der Horst, C. M., & Hennekam, R. C. (2008). Klippel-Trenaunay syndrome: Diagnostic criteria and hypothesis on etiology. *Annals of Plastic Surgery*, 60(2), 217–223. doi:10.1097/SAP.0b013e318062abc1
- Partsch, H. (2003). Understanding the pathophysiological effects of compression. In S. Calne (Ed.), *Position document: Understanding compression therapy* (pp. 2–4). London: Medical Education Partnership Ltd.
- Quérel, I., Presles, E., Coupé, M., Vignes, S., Vaillant, L., Eveno, D., ... Leizorovicz, A. (2014). Prospective multicentre observational study of lymphedema therapy: POLIT study. *Journal des maladies vasculaires*, 39(4), 256–263. doi:10.1016/j.jmv.2014.05.004
- Shirasugi, N., Horiguchi, S., Shirato, H., Kawakami, T., Ono, H., Yabuki, S., ... Niimi, M. (2016). Prevalence of isolated asymptomatic deep vein thrombosis in varicose vein patients with superficial thrombophlebitis: A single center experience in Japan. *Annals of Vascular Diseases*, 9(1), 2–7. doi:10.3400/avd.aa.15-00124
- Steinhausen, H. C. (1996). Psychosoziale Aspekte bei chronischen Krankheiten im Kindes- und Jugendalter [Psychosocial aspects of chronic diseases in children and adolescents]. *Dt. Ärzteztbl*, 93(40), A-2553–2555. German.
- Tan, I. C., Maus, E. A., Rasmussen, J. C., Marshall, M. V., Adams, K. E., Fife, C. E., ... Sevick-Muraca, E. M. (2011). Assessment of lymphatic contractile function after manual lymphatic drainage using near-infrared fluorescence imaging. *Archives of Physical Medicine and Rehabilitation*, 92(5), 756–764e1. doi:10.1016/j.apmr.2010.12.027
- Tian, X. L., Kadaba, R., You, S. A., Liu, M., Timur, A. A., Yang, L., ... Wang, Q. (2004). Identification of an angiogenic factor that when mutated causes susceptibility to Klippel-Trenaunay syndrome. *Nature*, 427(6975), 640–645. doi:10.1038/nature02320
- Tidhar, D., Armer, J. M., Deutscher, D., Shyu, C.-R., Azuri, J., & Madsen, R. (2015, Sep). Measurement issues in anthropometric measures of limb volume change in persons at risk for and living with lymphedema: A reliability study. *Journal Pers Medica*, 5(4), 341–353. doi:10.3390/jpm5040341
- Vignes, S., Porcher, R., Arrault, M., & Dupuy, A. (2011). Factors influencing breast cancer-related lymphedema volume after intensive decongestive physiotherapy. Supportive care in cancer. *Support Care Cancer*, 19(7), 935–940. doi:10.1007/s00520-010-0906-x
- Vollmer, A., Pritschow, H., & Schuchhardt, C. (2008). Theorie und Praxis der Kompressionsbestraufung venöser und lymphatischer Extremitätenödeme [Theory and practice of compression garments in venous and lymphatic limb disorders]. In H. Pritschow & C. Schuchhardt (Eds.), *Das Lymphödem und die Komplexe Physikalische Entstauungstherapie: Ein Handbuch für die Praxis in Wort und Bild*. 2 (pp. 191–231). Aufl. Essen, German: Viavital.
- Vojackova, N. J., V., Fialová, J., & Hercogová, J. (2012). Management of Lymphedema. *Dermatologic Therapy*, 25(4), 352–357. doi:10.1111/j.1529-8019.2012.01534.x

- Wang, Z. K., Wang, F. Y., Zhu, R. M., & Liu, J. (2010). Klippel-Trenaunay syndrome with gastrointestinal bleeding, splenic hemangiomas and left inferior vena cava. *World Journal of Gastroenterology : WJG*, 16 (12), 1548–1552.
- Williams, A. (2010). Manual lymphatic drainage: Exploring the history and evidence base. *Brit Journal Community Nursing*, 15(4), 18–24. doi:10.12968/bjcn.2010.15.Sup3.47365
- Witte, C. L., & Witte, M. H. (2000). An imaging evaluation of angiodysplasia syndromes. *Lymphology*, 33(4), 158–166.
- Witte, M. H., & Witte, C. L. (1987). Lymphatics and blood vessels, lymphangiogenesis and hemangiogenesis: From cell biology to clinical medicine. *Lymphology*, 20(4), 257–266.
- Worthington-Kirsch, R. L. (2005, September). Injection Sclerotherapy. *Seminars Intervent Radiology*, 22(3), 209–217. doi:10.1055/s-2005-921954
- Zusman, M., & Moog-Egan, M. (2003). Physiotherapie bei Schmerzproblemen [Physiotherapy with pain problems]. In F. Van Den Berg (Ed.), *Angewandte Physiologie Bd 4. Schmerzen verstehen und beeinflussen* (pp. 269–290). Stuttgart: Thieme.



© 2018 The Author(s). This open access article is distributed under a Creative Commons Attribution (CC-BY) 4.0 license.

You are free to:

Share — copy and redistribute the material in any medium or format.

Adapt — remix, transform, and build upon the material for any purpose, even commercially.

The licensor cannot revoke these freedoms as long as you follow the license terms.

Under the following terms:

Attribution — You must give appropriate credit, provide a link to the license, and indicate if changes were made.

You may do so in any reasonable manner, but not in any way that suggests the licensor endorses you or your use.

No additional restrictions

You may not apply legal terms or technological measures that legally restrict others from doing anything the license permits.

Cogent Medicine (ISSN: 2331-205X) is published by Cogent OA, part of Taylor & Francis Group.

Publishing with Cogent OA ensures:

- Immediate, universal access to your article on publication
- High visibility and discoverability via the Cogent OA website as well as Taylor & Francis Online
- Download and citation statistics for your article
- Rapid online publication
- Input from, and dialog with, expert editors and editorial boards
- Retention of full copyright of your article
- Guaranteed legacy preservation of your article
- Discounts and waivers for authors in developing regions

Submit your manuscript to a Cogent OA journal at www.CogentOA.com

